

A TRANSMISSIBLE AVIAN NEOPLASM.¹
(SARCOMA OF THE COMMON FOWL.)

BY PEYTON ROUS, M.D.

(From the Laboratories of the Rockefeller Institute for Medical Research,
New York.)

PLATES LXVI-LXVIII.

Among the many recent observations on transmissible neoplasms are several which may have greatly enlarged our knowledge of tumor behavior and certainly, for the present, have somewhat confused it. The tumors of the lower animals first studied experimentally—those of the rat and mouse—were found to conduct themselves much as do human neoplasms; and results with them rather strengthened than changed our conception of tumor-characters. But there have since been discovered a number of transmissible new growths of unusual behavior, among them a sarcoma of the dog, transmissible at coitus (Sticker, Ewing), an endemic carcinoma of fishes (Plehn, Pick, Gaylord), and a new growth of hares (von Dungern and Coca), transplantable to animals of another species. All of these in their conduct differ more or less markedly from the classical neoplasms, and whether they are to be accepted as genuine tumors is still doubtful. On the other hand, it is possible that our conception of tumor-behavior, based as it is on observations among few species, has been too narrow.

At this time then the discovery and study of transmissible tumors in new species or classes of animals has an exceptional value. And it is for such reason that a sarcoma of the chicken—the first avian tumor which has proved transplantable to other individuals—will here be dealt with in some detail.

New growths are not rare among birds, and those of the common fowl have had attention from several investigators. Fibromas, myomas, lymphomas, carcinomas and sarcomas, some of them with

¹Received for publication June 13, 1910.

metastases, have been described. Ehrenreich,² and Tyzzer and Ordway³ have made attempts at transplantation, but without success, if one except an auto-transplantation of a lymphoma accomplished by the latter authors. Ellerman and Bang⁴ have shown chicken leukemia to be transmissible, and in some of their animals aleukemic lymphomata resulted from inoculation. But they have also shown, as have Hirschfeld and Jacoby,⁵ that the disease is dependent on a filterable virus.

The tumor here reported was found in a barred Plymouth Rock hen of light color and pure blood. It had existed for some two months before the fowl was brought to the laboratory, becoming noticeable when the host was about fifteen months old. The sarcoma described by Ehrenreich and the myxosarcoma of Tyzzer both occurred in adult fowls.

In this hen there was present, projecting sharply from the right breast, a large, irregularly globular mass. It had developed slowly, and without apparent involvement of the health of the host. Operation was done under ether and nearly all of the growth removed. When sliced it was found to have undergone a widespread coagulation-necrosis at the center, but there was a rim of translucent, rather friable, yellowish-pink tissue of glistening, finely striated surface. Macroscopically, the growth suggested a sarcoma. Bits of it were at once inoculated by means of a trocar into the other breast and peritoneal cavity of the host. Like inoculations were also made into two hens from the same setting of eggs. Thirty-five days later the original host was dead of intraperitoneal growths, and in the breast of one of the other fowls, a large nodule had developed. A summary of the protocols follows.

Oct. 1, 1909. *Operation on Original Tumor.*—The fowl bearing the growth is a strong, young hen. The mass is situated on the right breast, in the subcutaneous tissue, and is somewhat movable. It is irregularly spherical in shape, firm, smooth, well-defined, and projects sharply from the breast contour. It

² M. Ehrenreich and L. Michaelis, *Zeit. f. Krebsforsch.*, 1906, iv, 586; M. Ehrenreich, *Med. Klin.*, 1907, iii, 614.

³ E. E. Tyzzer and T. Ordway, *Jour. of Med. Research*, 1909, xxi, 459.

⁴ V. Ellerman and O. Bang, *Cent. f. Bakt., Orig.*, 1908, xlvi, 595; *Zeit. f. Hygiene u. Infektionskrank.*, 1909, lxiii, 231.

⁵ H. Hirschfeld and M. Jacoby, *Zeit f. klin. Med.*, 1909-10, lxix, 107.

measures 4.8 by 4.1 by 4.1 centimeters. At its outer pole the skin is attached and thinned, with several slight ulcerations over which are dry, dark-red crusts. Elsewhere, the skin is uninvolved, though the subcutaneous fat is thinned.

Under ether most of the mass was to-day excised, a piece 1 by 3 by 0.5 centimeters being left *in situ*. The growth shelled out easily from the surrounding tissue, and was enclosed in a capsule well supplied with blood-vessels.

The part removed is found on section to consist of a rim of translucent, rather friable tissue about a center that has undergone coagulation necrosis and is firm, yellow and opaque. The rim-tissue is glistening, yellowish-pink, finely striated. No debris comes away from it on scraping, and its surface remains smooth. The region of coagulation-necrosis is serpiginous in outline and forms much the larger part of the mass.

Implantation was made by means of a large trocar into the muscles of the left breast of the same fowl and also into the peritoneal cavity. Bits of the tumor-rim approximating 0.03 cubic centimeter were thrust into each site. Similar implantations were carried out on two young hens of the same brood. No cultures were taken at this time.

Nov. 5, 1909. *Autopsy of the Tumor Fowl, Which Died Yesterday.*—The fragment of the original growth is no longer to be found, but in the muscle of the left breast is an ovoid mass 1.5 by 1.5 by 2.2 centimeters, with similar necrotic center and translucent marginal zone. It has no definite capsule and is not sharply separated from the muscle about it. The peritoneal cavity contains about 20 cubic centimeters of a thin, straw-colored fluid. Attached to the lower margin of the liver, to the oblique membrane, and to the parietal peritoneum are many firm, pale yellow, ovoid or globular nodules, the largest about 1 centimeter in diameter. On section these resemble the nodule in the left breast, except that in them the necrosis is irregularly distributed. At the pelvic region, where several of the masses have coalesced, softening and necrosis are extensive. Smears from fragments taken here show no tubercle bacilli; but with aqueous methylene blue a large rod-shaped bacillus, presumably a post-mortem invader, is demonstrable. No growths are present in the other organs.

Nov. 5, 1909. In the muscle of the left breast of one of the young hens inoculated on October 1 is a firm mass measuring 2.5 by 3.5 centimeters. (The remainder of this protocol is given further on.)

Microscopic preparations of the original growth, and of the nodules developing elsewhere in the host on implantation, have shown it to be a spindle-celled sarcoma. The growths from all latter transplantations have yielded similar pictures, so the histology of the tumor will now be taken up.

In a typical section one observes loose bundles of spindle-cells coursing in every direction, and separated from the lesser blood-vessels only by endothelium (Plate LXVII, Figs. 3 and 4). Where such a bundle is cut transversely, the appearance is that of a group of round cells of varying sizes. With Mallory's phosphotungstic

acid stain intercellular fibrils are demonstrable, though they are rare in the more cellular portions of the growth. The spindle cells, while in general large, vary much in size and shape; some are short and plump, some continued into long, slender processes. The nucleus is, as a rule, large and vesicular, with a loose network and several coarse masses of chromatin. Occasionally, it is rod-shaped, and not seldom pyknotic. To the more slender cells, it gives a bulged outline at that region where it is located. Mitosis is fairly frequent and cells with two to five or six nuclei are not rare. These small giant-cells give to the growth here and there a somewhat polymorphous appearance. They are especially to be found where necrosis is beginning. The widespread necrosis seems in general dependent on insufficient vascularization, although hemorrhage from the thin-walled vessels is also occasionally responsible. In some of the later growths a myxomatous degeneration has separated the cells, and in at least one there has followed a liquefaction with formation of a cyst.

The original tumor was better encapsulated than those resulting on transplantation. Indeed, it gave clinically the picture of a benign growth until after its dissemination at operation. The apparent liberation from restraints that took place then is a phenomenon that has been noted by others⁶ for the neoplasms of rats and mice. Infiltration has been the rule since. Search shows that it was also present to some extent in the original growth before operation, despite the considerable encapsulation. The tumor cells had pressed through this capsule here and there and invaded the muscle. The muscle fibers in their breaking down furnished on transverse section some remarkable pictures of pseudo-giant-cells (Plate LXVIII, Fig. 5).

Following the growth's successful transplantation, an attempt was made to propagate it further. At this writing, it is in its fourth generation. The results bring out in an interesting way the importance of blood-relationship to the transmission. The tumor has never thriven except in the intimately related fowls of the pure-blood stock in which it was first noticed. The members of this stock were few and their relationship to one another can be stated with considerable accuracy.

⁶L. Loeb, *Jour. of Med. Research*, 1901, vi, 28.

The tumor was found in one of six hens of pure blood from the same setting, and these, with a single cock of pure blood from another source, formed the parent birds of the stock. From them a single generation of chickens had been raised when the tumor was noted. For the first transplantation two of the parent hens (of the same setting as the tumor fowl) were used, but in the later ones the younger generation of chickens was employed. These, which numbered in all only between twelve and fifteen, had at least one parent in common, some of them two, and some may have been the offspring of the tumor hen, or of that in which the neoplasm grew on its first transplantation. It would be interesting to know the exact relationship between these two hens and the young fowls that proved susceptible, but that cannot be ascertained because the eggs were mixed indiscriminately for setting. Yet it is evident enough that the relationship between all of the fowls of the special stock was a very close one.

Out of twelve of this stock to which it has been transplanted, the tumor has grown in three, and they have been the hosts for the tumor generations thus far accomplished.⁷ In sixteen market-bought Plymouth Rocks, superficially like the tumor stock but presumably of impure blood, no growth has been obtained; nor has it occurred in five chickens of mixed breed. In two of three market-bought Plymouth Rocks, which were less than three months old, a transient growth, followed by retrogression, was noted (Chart 1). In two pigeons and in two guinea pigs the results have been negative.

The transplantation appears to succeed better in young fowls, judging from its partial success in the young, market-bought Plymouth Rocks and its complete failure in adults of the same sort. At present, the tumor, while still growing in hosts of the special stock, is growing slowly; slow growth may be attributable to the fact that no young fowls are available, for all of the chickens of the second generation of this stock are now adult.

Only two fowls thus far have died as a result of the tumor, which attains a large size before the general health is much affected.

⁷ Since this was written transplantation to similar fowls of pure blood from another source has proven successful.

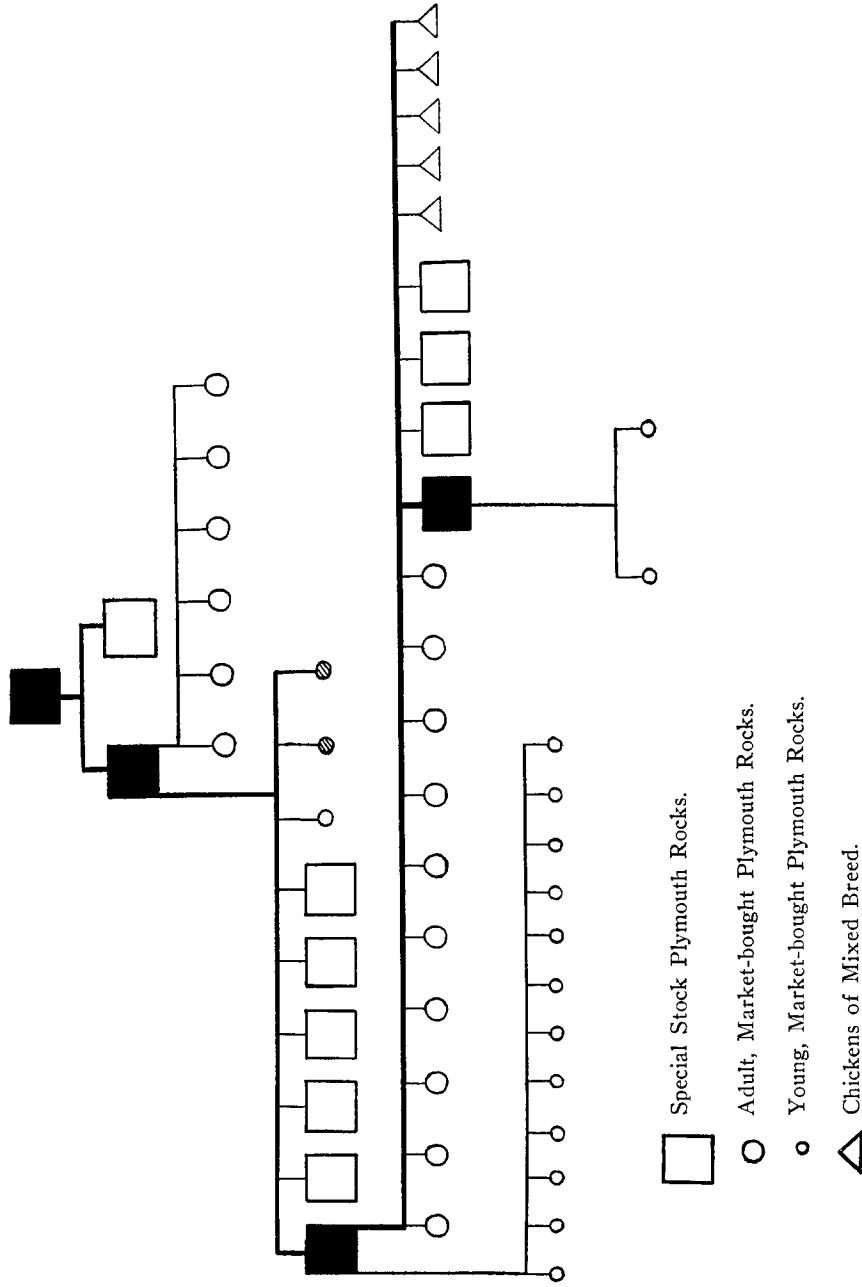


CHART I. Chart showing the course of transmission of the chicken sarcoma. The blackened figures represent individuals in which the tumor grew; the cross-bared ones those in which a nodule appeared but retrogressed.

(Plate LXVI, Figs. 1 and 2). Thorough bacteriological examinations of the neoplasm have twice been made at operation, but with negative results. Metastasis has occurred once, a tumor nodule being found in the left ventricle of a hen (second generation B) from which the growth had been partially removed some weeks previously (Plate LXVIII, Fig. 6). Whether the operative procedure or a natural dissemination was responsible for this metastasis cannot, of course, be determined. Many intraperitoneal inoculations, and reinoculations of negative individuals have been made, but growth has followed none of these.

A brief summary of the remaining protocols to date will now be given.

First Generation A.—Nov. 8, 1909. One of the 2 young hens inoculated with bits of the original growth was observed 3 days ago to have in the left breast a mass measuring 2.5 by 3.5 centimeters. This was operated upon today and found to be a tumor-nodule. Bits of it were transferred with the trocar to the fowls of *second generation A*.

Dec. 12, 1909. Following operation on the nodule it grew rapidly and to-day measured 5.3 by 4 by 3.5 centimeters, when it was again cut into for the sake of inoculation to *second generation B*. Hemorrhage was so profuse, and the mass was found to extend so deeply into the breast tissue that the fowl was killed. At autopsy, in addition to the mass on the breast, there was present a discrete, firm, translucent, grayish-pink nodule, 0.4 centimeter in diameter, in the substance of the left ventricle. Microscopically, this proved to be a metastasis. The other organs were normal. Fragments of the large growth were placed in bouillon and litmus milk, on sheep-serum agar, plain agar, and Loeffler's blood-serum. Also cultures were taken on gelatine, glucose bouillon, potato, the peptone medium, and glucose agar. These were under observation for several weeks. Bacterial growth occurred in none of them. The Loeffler's blood serum was quite actively digested by the fragment resting on it. Direct smears from the fresh tissue were examined for bacteria, including acid-fast bacilli, but with negative results.

May, 1910. The other animal of *first generation A* has remained free of tumor and healthy to date.

Second Generation A.—Nov. 8, 1909. Six market-bought Plymouth Rock chickens, 2 pigeons and 2 guinea-pigs were inoculated with tumor-bits in the muscle of the right breast and also intraperitoneally. The material was obtained from *first generation A* (q. v.).

Jan. 27, 1910. The chickens were reinoculated, this time into the left breast, with material from *second generation B*.

May, 1910. All are still without sign of tumor.

Second Generation B.—Dec. 10, 1909. Three market-bought Plymouth Rock chickens less than 3 months old, and 6 young fowls, 6 months old, of the tumor

stock, were inoculated in both breasts with bits of the growth from the positive fowl of *first generation A*. The 3 market-bought chickens sickened and died within 12 weeks thereafter. In one was no trace of tumor; in the second was a small nodule (0.6 centimeters in diameter) that had undergone myxomatous degeneration; in the third, a small cyst (1.0 centimeters broad), formed by degeneration and liquefaction of tumor-tissue. Some fragments of this tissue still existed at the well-encapsulated periphery of the cyst.

Jan. 17, 1910. Of the 6 fowls from the tumor stock one had developed at this date a tumor mass 1.3 centimeters in diameter. Jan. 27, 1910. The nodule measured 2.5 centimeters and was operated upon for transfer into *third generation A* (q. v.) and for reinoculation of *second generation A*. At this time many cultures were taken and stains made for bacteria but with negative results. During the next few weeks, the mass decreased in size, and no sign of renewed growth was observed until March 21, 1910. April 7, 1910. Growth has of late been rapid and the mass when today cut into measured 4 by 3 by 2 centimeters. Inoculation was done into *third Generation B*. April 18, 1910, the mass operated upon measured 5 by 3.3 by 2.5 centimeters and was approximately egg-shaped, firm and smooth (Plate LXVI, Fig. 1). The wound had healed perfectly.

In none of the other fowls of this generation was growth obtained.

Third Generation A.—Jan. 27, 1910. Five young fowls of mixed breed, 10 market-bought Plymouth Rocks, and 4 chickens, seven months old, of the tumor-stock were inoculated from *second generation B*.

May 9, 1910. To date none have shown tumors except a cock of the tumor-stock in which was noted March 21 a small lump on the left breast. Operation was performed April 7, and inoculation made into *fourth generation A*.

Third Generation B.—April 7, 1910. Twelve market-bought Plymouth Rocks, under 3 months of age, were inoculated in the muscle of both breasts and in the subcutaneous tissue of the left breast with material from *second generation B*. June 1, 1910. In none of these has growth appeared.

Fourth Generation A.—April 7, 1910. Two of the young fowls inoculated on this date received in the right breast material from *third generation A* instead of from *second generation B*. June 1, 1910. Both of these are negative as regards tumor.

So far as tested this new growth in the chicken has proved itself a neoplasm of classical behavior. The peculiarities which it exhibits are those already made familiar through observations on the tumors of the rat, mouse, dog and man. The tissue specificity which has limited its successful transplantation to fowls of the stock in which the primary growth arose is striking, but not more so than the specificity of certain mouse and rat tumors; and this character may in part explain why previous attempts to transplant neoplasms of the fowl have failed.

The tumor is at best so difficult of propagation that no attempts have been made to determine whether it can be transmitted by cell-

fragments, or by cell-free derivatives. For the same reason, the question whether growth takes place entirely from the introduced cells has not been investigated. But there is no reason to suspect that the neoplasm will differ on these points from the better-known tumors of mammals.

It may not be superfluous to point out that such similarity of behavior as has been thus far observed between this avian tumor and those of mammals was, after all, largely to be expected. A graft of mammalian tumor succeeds better in a blood-related individual, and a young one, not because it is tumor, but because it is tissue. The tissue laws here concerned are probably not very different in birds. Nevertheless, the close correspondence in behavior between this avian tumor and the typical mammalian tumors is certainly of interest. Sticker's lymphosarcoma of the dog, which is transplantable to foxes, von Dungern's tumor of the hare, which will also grow in rabbits, both deviate more from the tumor-type as observed in mammals than does this sarcoma of the fowl. At first sight, indeed, the behavior of these unusual growths seems in absolute violation of the laws governing tissues. Yet this is not necessarily true. For in the hybridization of the horse with the ass, of the dog with the wolf, the elements from different species unite in a much more intimate association than exists between a tumor and its host.

SUMMARY.

In this paper is reported the first avian tumor that has proved transplantable to other individuals. It is a spindle-celled sarcoma of the hen, which thus far has been propagated into its fourth tumor generation. This was accomplished by the use of fowls of pure blood from the small, intimately related stock in which the growth occurred. Market-bought fowls of similar variety have shown themselves insusceptible, as have fowls of mixed breed, pigeons and guinea-pigs. The percentage of successful transplantations has been small, but in the individuals developing a tumor its growth has been fairly rapid. Young chickens are more susceptible than adults. The reinoculation of negative fowls has never resulted in a growth.

Throughout, the sarcoma has remained true to type. It is

infiltrative and destructive. Metastasis has been observed once (to the heart). Experiments to determine whether the growth may be transmitted by cell-fragments have not yet been made. Repeated bacteriological examinations have yielded negative results.

In its general behavior, so far as tested, this avian tumor closely resembles the typical mammalian neoplasms that are transplantable.

EXPLANATION OF PLATES.

PLATE LXVI.

FIG. 1. Sarcoma. Second generation B.

FIG. 2. Cross-section of same tumor, somewhat enlarged.

PLATE LXVII.

FIG. 3. Sarcoma of the chicken from an intraperitoneal growth.

FIG. 4. Sarcoma of the chicken.

PLATE LXVIII.

FIG. 5. Invasion of muscle by the sarcoma.

FIG. 6. A metastasis in the heart wall. The lumen shown at the left hand corner is that of a small vein.

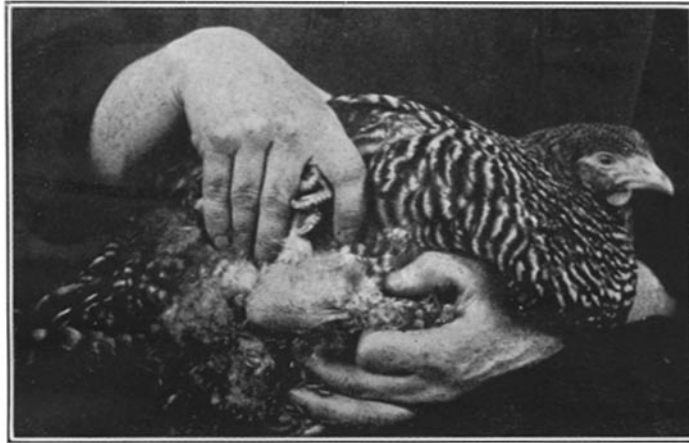

FIG. 1.

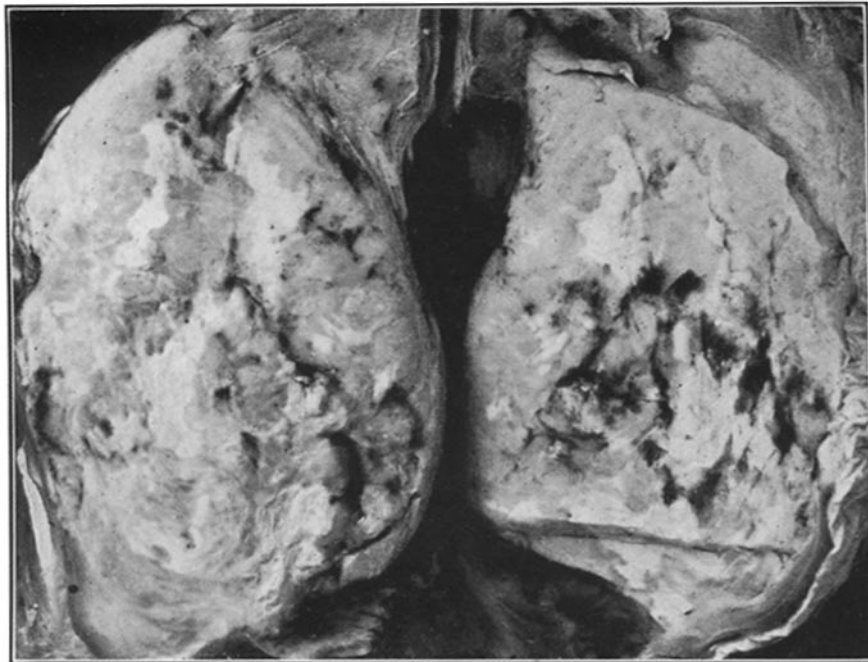

FIG. 2.

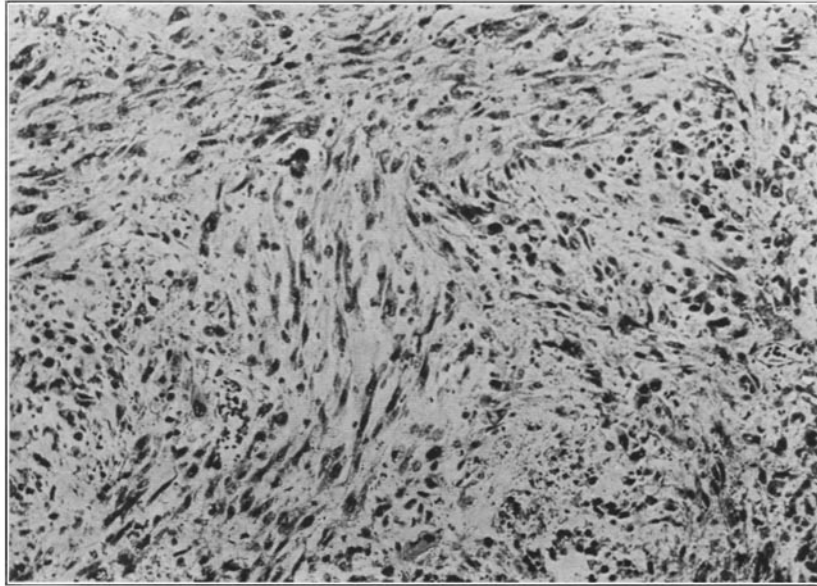


FIG. 3.

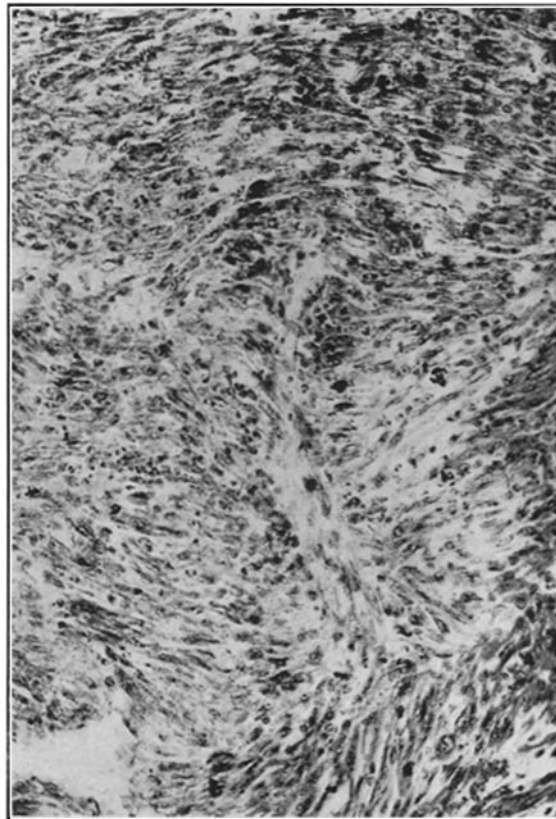


FIG. 4.

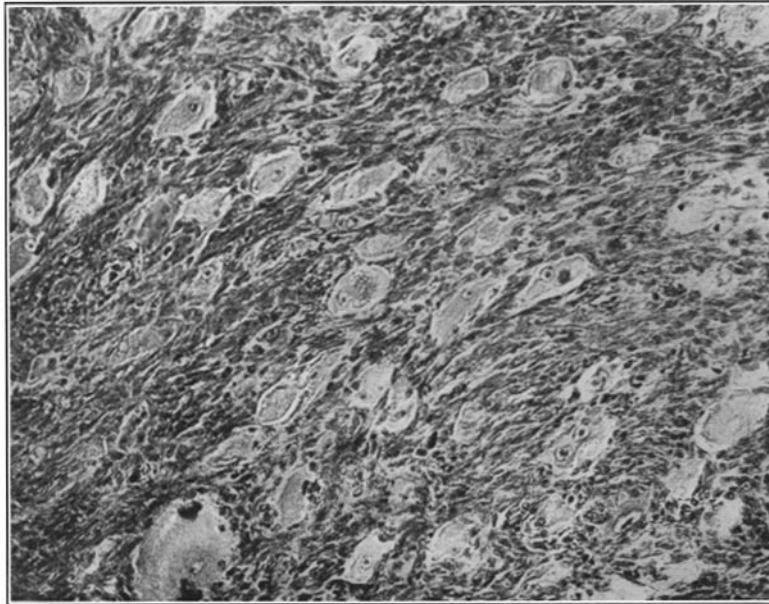


FIG. 5.



FIG. 6.